

International Collating Centre: Summary Report

(1 April to 30 June 2023)

The International Collating Centre (ICC), is overseen by Equine Infectious Disease Surveillance (EIDS) and is generously supported by contributions from Fédération Equestre Internationale (FEI), International Thoroughbred Breeders' Federation (ITBF) members, Japanese Racing Association and Lanwades Stud.



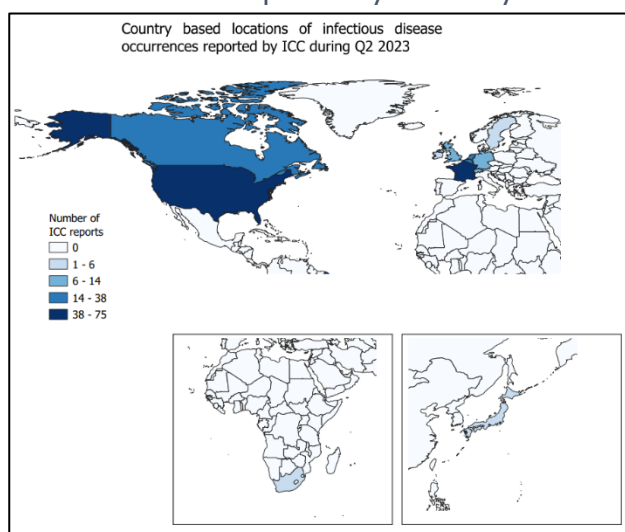
**International
Collating Centre**

National and international equine disease outbreaks are reported on a daily basis by the ICC, through email alerts. Please contact equinesurveillance@gmail.com to receive these. There is also a website available that provides an interactive interface of these infectious disease reports and can be used to view current outbreak reports, <https://equinesurveillance.org/iccview/>.

This article provides a summary of international disease outbreaks during the second quarter of 2023. It should also be noted that additional summary reports were kindly received that included further information on disease occurrence for that country, but which had not been reported in previous real-time ICC reports. This additional information is identified by *or # in the tables and text, where relevant, throughout this report.

The data presented in this report *must be interpreted with caution*, as there is likely to be some bias in the way that samples are submitted for laboratory testing and subsequently reported. Consequently, these data do not necessarily reflect true infectious disease frequency within the international equine population. A country with no reported outbreaks of a disease does not necessarily equate to the disease not being present in that country. Each table below summarises the number of disease outbreaks reported by a country. Each reported outbreak may involve more than one animal.

During Q2 2023, the ICC shared 267 outbreak reports obtained from 12 countries (shaded on the map). Of specific diseases/infections reported, strangles (n=104), equine influenza (n=29) and equine herpes virus-4 (n=28) were the most widely reported. Neurological (n=20), reproductive (n=13) and respiratory (n=15) forms of equine herpes-1 were the next most reported infections.



Reproductive Diseases

Country	CEM	EHV-1	EHV-1/-4	EHV-3	EHV-4	<i>Strep. zooepidemicus</i>
Belgium	-	4	1	-	1	-
Canada	-	1	-	-	-	-
France	-	1	-	1	-	1
Germany	3	2	-	-	-	-
Japan	-	#1	-	-	-	-
Netherlands	-	1	-	-	-	-
UK	-	3	-	-	-	-

#some cases reported by ICC after the quarter end

Contagious Equine Metritis (CEM)

Germany



Three outbreaks of CEM were reported. Two outbreaks involved single cases on premises in Bavaria and Hesse and one outbreak involved three cases on a premises in Lower Saxony. Positive diagnoses were confirmed by PCR on genital swabs.

Equine Herpes Virus-1 (EHV-1) Abortion

Belgium



Four outbreaks of EHV-1 abortion were reported. Three outbreaks involved single cases on premises in Antwerp, Flemish Brabant and West Flanders and one outbreak involved five cases in unvaccinated mares on a premises in Flemish Brabant. Positive diagnoses were confirmed by PCR on fetal tissues.

Canada



One case of EHV-1 abortion was reported in an unvaccinated mare on a premises in Ontario, with three further suspected cases on site.

France



One case of EHV-1 abortion was reported in a vaccinated Thoroughbred mare on a premises in Orne. Positive diagnosis was confirmed by PCR on fetal material.

Germany



Two outbreaks of EHV-1 abortion, each involving single cases, were reported on premises in Lower Saxony and Mecklenburg-Western Pomerania. Positive diagnoses were confirmed by PCR on nasal and genital swabs from the mares and lung tissue from one of the fetuses.

Japan



#One case of EHV-1 abortion was reported, after the quarter end, in a vaccinated Thoroughbred. Positive diagnosis was confirmed by loop mediated isothermal amplification (LAMP)

Netherlands



One outbreak of EHV-1 abortion, involving two unvaccinated mares, was reported on a premises in Flevoland. Positive diagnoses were confirmed by PCR.

UK



Three outbreaks of EHV-1 abortion/neonatal foal death, each involving single cases, were reported. The two outbreaks involving neonatal foal death occurred on premises in North Yorkshire and Rutland. The outbreak of EHV-1 abortion was in an unvaccinated mare on a premises in Warwickshire. Positive diagnoses were confirmed by PCR on fetal and placental tissue and cerebrospinal fluid.

Equine Herpes Virus-1/-4 (EHV-1/-4) Abortion

Belgium



One outbreak of EHV-1/-4 abortion, involving a single case, was reported on a premises in Liege. Positive diagnosis was confirmed by PCR on fetal tissue. It was noted that there had been further incidences of abortion on the affected premises.

Equine Herpes Virus-3 (EHV-3) equine coital exanthema

France



One outbreak of EHV-3 equine coital exanthema, involving a single case, was reported on a premises in Mayenne. Positive diagnosis was confirmed by PCR on a genital swab.

Equine Herpes Virus-4 (EHV-4) Abortion

Belgium



One outbreak of EHV-4 abortion, involving a single case, was reported on a premises in Hainaut. Positive diagnosis was confirmed by PCR on fetal tissue.

Streptococcus zooepidemicus abortion

France



One case of *Strep. zooepidemicus* abortion was reported on premises in Vosges. Positive diagnosis was confirmed by PCR on placental tissues.

Respiratory Conditions

Country	EHV-1	EHV-1 & 4	EHV-2	EHV-2 & 5	EHV-4	Influenza	R. equi	Strangles
Belgium	-	-	2	1	2	5	-	1
Canada	-	-	-	-	-	7	-	10
France	1	1	-	-	9	5	11	23
Germany	5	-	-	-	1	2	-	1
Ireland	#8	-	-	-	-	-	-	-
Netherlands	1	-	-	-	10	1	-	25
South Africa	#1	-	-	-	#2	-	-	-
Switzerland	-	-	-	-	3	-	-	4
UK	1	-	-	-	3	5	-	-
USA	4	-	-	-	-	4	-	40

#some cases reported to ICC after the quarter end

Equine Herpes Virus-1 (EHV-1) Respiratory Infection

France



One case of EHV-1 respiratory infection with a co-infection of adenovirus-1 in a vaccinated gelding, was reported on a premises in Cote-d'Or. Clinical signs included pyrexia and nasal discharge. Positive diagnosis was confirmed by PCR on a nasopharyngeal swab.

Germany



Five outbreaks of EHV-1 respiratory infection with single cases in each were reported on premises in Lower Saxony and Schleswig-Holstein. Positive diagnoses were confirmed by PCR on nasal swabs and serology.

Ireland



#Eight outbreaks of EHV-1 respiratory infection were reported in Ireland after the quarter end. Seven involved single cases and one outbreak had four cases.

Netherlands



One case of EHV-1 respiratory infection was reported on a premises in Friesland. Positive diagnosis was confirmed by PCR.

South Africa



#During 2Q 2023, SAEHP reported one case of EHV-1 respiratory infection in the North West Province after the quarter end.

UK



One case of EHV-1 respiratory infection was reported in an unvaccinated Sports Horse mare on a premises in North Yorkshire. Clinical signs included: pyrexia and mucoid nasal discharge. Positive diagnosis was confirmed by PCR on a nasopharyngeal swab.

USA



Four outbreaks of EHV-1 respiratory infection were reported. Two of the outbreaks involved single cases, one with a co-infection of equine influenza and *Streptococcus zooepidemicus* respiratory infection, on premises in Oregon and Wisconsin. Two outbreaks involved two cases on premises in North Dakota and Wisconsin. Clinical signs included: mucopurulent nasal discharge, pyrexia and respiratory signs.

Equine Herpes Virus-1/-4 (EHV-1/-4) Respiratory Infection

France



One case of EHV-1/-4 respiratory infection with a co-infection of *Streptococcus equi* was reported on a premises in Yvelines. Positive diagnosis was confirmed by PCR on a nasopharyngeal swab.

Equine Herpes Virus-2 (EHV-2) Respiratory Infection

Belgium



Two outbreaks of EHV-2 respiratory infection, with single cases in each, were reported on premises in Hainaut and Limburg. Clinical signs included: cough, nasal discharge and pyrexia. Positive diagnoses were confirmed by PCR on nasal swabs.

Equine Herpes Virus-2/-5 (EHV-2/-5) Respiratory Infection

Belgium



One case of EHV-2/-5 respiratory infection was reported on a premises Hainaut. Clinical signs included: cough, nasal discharge and pyrexia. Positive diagnosis was confirmed by PCR on a nasal swab.

Equine Herpes Virus-4 (EHV-4) Respiratory Infection

Belgium



Two outbreaks of EHV-4 respiratory infection were reported, each involving single cases, on premises in: East Flanders and Hainaut. Clinical signs included: cough, lymphadenopathy, nasal discharge and pyrexia. Positive diagnoses were confirmed by PCR on nasal swabs.

France



Nine outbreaks of EHV-4 respiratory infection were reported. Eight of the outbreaks involved single cases on premises in; Bouches-du-Rhone, Calvados, Correze, Orne and Vosges. One case had a co-infection of EHV-2, EHV-5 and ERBV. One outbreak consisted of two cases on a premises in Calvados. Clinical signs included: lymphadenopathy, nasal discharge and pyrexia. Positive diagnoses were confirmed by PCR on nasopharyngeal swabs and in one case by PCR on a tracheal wash.

Germany



One case of EHV-4 respiratory infection was reported on a premises in North Rhine-Westphalia. Positive diagnosis was confirmed by PCR on a nasal wash.

Netherlands



Ten outbreaks of EHV-4 respiratory infection were reported. Seven of the outbreaks involved single cases on premises in: Friesland, North Brabant, South Holland. Three outbreaks involved more than one case, on premises in: Friesland and Overijssel. Positive diagnoses were confirmed by PCR.

South Africa



#During the 2Q 2023, SAEHP reported two outbreaks of EHV-4 respiratory infection with one case in each on separate premises in Mpumalanga and the Northern Cape after the quarter end.

Switzerland



Three outbreaks of EHV-4 respiratory infection were reported. Two outbreaks involved single cases on premises in the cantons of Bern and Thurgau. One outbreak involving more than one case was on a premises in the Canton of Zurich. Positive diagnoses were confirmed by PCR

UK



Three outbreaks of EHV-4 respiratory infection, involving single single cases in each, were reported on premises in; Devon, Lancashire and Norfolk. Clinical signs included: cough, inappetence, lethargy, lymphadenopathy, pyrexia and nasal discharge. Positive diagnoses were confirmed by PCR on nasopharyngeal swabs.

Equine Influenza (EI)

Belgium



Five outbreaks of EI were reported, each involving single cases, on premises in: East Flanders and Hainaut. Clinical signs included: cough, lymphadenopathy, nasal discharge and pyrexia. Positive diagnoses were confirmed by PCR on nasal swabs.

Canada



Seven outbreaks of EI were reported. Six outbreaks involved single cases on separate premises in Quebec. One outbreak involved two cases on a premises in Alberta. Clinical signs included: cough, nasal discharge, pyrexia and respiratory signs.

France



Five outbreaks of EI were reported. Three outbreaks consisted of single cases on premises in: Calvados and Seine-Maritime. One outbreak consisted of two animals on a premises in Gironde and one outbreak consisted of five animals on a premises in Bouches-du-Rhone. Clinical signs included: cough, lymphadenopathy, nasal discharge and pyrexia. Positive diagnoses were confirmed by PCR on nasopharyngeal swabs.

Germany



Two outbreaks of EI, with single cases in each, were reported on premises in; Bavaria and North Rhone-Westphalia. Positive diagnoses were confirmed by PCR on nasal swabs.

Netherlands



One case of EI was reported on a premises in Overijssel. Positive diagnosis was confirmed by PCR.

UK



Five outbreaks of EI, each consisting of single cases, were reported on premises in; Cheshire, East Lothian, West Sussex and Worcestershire. Clinical signs included: cough, inappetence, lethargy, lymphadenopathy, nasal discharge and pyrexia. Positive diagnoses were confirmed by PCR on nasopharyngeal swabs.

USA



Four outbreaks of EI were reported. Three outbreaks consisted of single cases on separate premises in Washington. One outbreak consisted of two cases also on a premises in Washington.

Strangles

Belgium



One case of strangles was reported on a premises in West Flanders. Clinical signs included: cough, lymphadenopathy, nasal discharge and pyrexia. Positive diagnosis was confirmed by PCR on a nasal swab.

Canada



Ten outbreaks of strangles were reported. Nine of the outbreaks involved single cases on separate premises in; Alberta and Ontario. One outbreak consisted of two cases on a premises in Alberta. Clinical signs included: lethargy, nasal discharge, oedema of the head and a single limb, pyrexia, recumbency, respiratory distress, submandibular swelling and tachycardia. When reported, positive

diagnoses were confirmed by PCR in one case and bacterial culture in another case.

France



Twenty-three outbreaks of strangles were reported. Twenty-one outbreaks involved single cases on separate premises in; Ariège, Bas-Rhône Calvados, Dordogne, Essonne, Haute-Garonne, Haute-Saône, Jura, Loire Atlantique, Manche, Orne, Rhône, Sarthe, Seine-et-Marne and Vosges. Two outbreaks consisted of two cases on premises in Essonne and Rhône, with one of the animals having a co-infection of equine rhinitis B virus (ERBV). Clinical signs included: cough, dysphagia, lymphadenopathy, nasal discharge and pyrexia. Positive diagnoses were confirmed by PCR on nasopharyngeal/nasal swabs and by PCR on guttural pouch washes.

Germany



One case of strangles was reported on the Swiss-German border. Clinical signs included pyrexia. Positive diagnosis was confirmed by PCR.

Netherlands



Twenty-five outbreaks of strangles were reported. Eleven involved single cases on separate premises in; Friesland, Limburg, North Brabant, North Holland, Overijssel, South Holland. Fourteen outbreaks involving more than one case were on premises in: Drenthe, Friesland, North Brabant, North Holland, South Holland, Overijssel and Utrecht. Positive diagnoses were confirmed in the majority of cases by PCR.

Switzerland



Four outbreaks of strangles involving single cases, were reported, on premises in the cantons of Aargau, Lucerne and Zurich. Clinical signs included: pyrexia and respiratory tract signs. Positive diagnoses were confirmed by PCR in the majority of the outbreaks.

USA



Forty outbreaks of strangles were reported, 37 of which involved single cases on premises in; Florida, Indiana, Kansas, Kentucky, Michigan, Missouri, Oregon, Washington. Three outbreaks involved two cases on premises in Florida and Wisconsin, and one outbreak involved three cases on a premises in Colorado. Three outbreaks consisted of two cases on premises in: Florida, Kentucky and Michigan. Clinical signs included: abscessation, anorexia, difficulty swallowing, dyspnoea, enlarged lymph nodes, guttural pouch empyema, lethargy, lymphadenopathy, nasal discharge, purulent discharge draining from the submandibular lymph nodes, pyrexia, respiratory noise at exercise, submandibular swelling and unilateral facial swelling.

Gastrointestinal Diseases

Country	Equine Coronavirus	Rotavirus	Salmonellosis
France	-	9	-
Switzerland	1	-	-
USA	-	-	1

#some cases reported by ICC after the quarter end

Equine Coronavirus

Switzerland



One outbreak of Coronavirus was reported on a premises in the Canton of Bern. Clinical signs included: anorexia and pyrexia. Positive diagnosis was confirmed by PCR on faecal samples

Rotavirus

France



Nine outbreaks of rotavirus were reported. Eight involved single cases on separate premises in; Calvados, Charente, Lot-et-Garonne, Mayene and Orne. One outbreak involved two cases on a

premises in Calvados. Positive diagnoses were confirmed by PCR on rectal swabs or faecal samples.

Salmonellosis

USA



One case of salmonellosis was reported on a premises in Missouri. Clinical signs included: pyrexia,

Neurological Diseases

inappetence and colic signs.

Country	EEE	EEV	EHV-1	EHV-4	WNV
Belgium	-	-	1	-	-
Canada	-	-	4	-	-
France	-	-	1	1	-
South Africa	-	#43	-	-	#1
Sweden	-	-	1	-	-
UK	-	-	1	-	-
USA	4	-	12	-	1

#some cases reported by ICC after the quarter end

Eastern Equine Encephalitis (EEE)

USA



Four outbreaks of EEE, each involving single cases, were reported on separate premises in Florida. Clinical signs included: depression, incoordination, lateral recumbency with inability to rise, lethargy, lip twitching, muscle fasciculations, pyrexia and tremors.

Equine Encephalosis Virus (EEV)

South Africa



#EEV is regarded as endemic in South Africa with cases reported as follows after the quarter end: Free State (one case), Gauteng (17 cases), Kwa-Zulu Natal (seven cases), Mpumalanga (five cases), Northern Cape (three cases), North West Province (two cases) Western Cape (one case) and Limpopo (seven cases).

Equine Herpes Virus-1 (EHV-1) Neurological Disease

Belgium



One outbreak of EHV-1 neurological disease was reported on a premises in East Flanders which also reported concurrent cases of EHV-1 abortion. Reported cases included: 10 cases of paralysis, requiring euthanasia, eight cases of abortion, three case of neonatal death and two cases of ataxia. Positive diagnoses were confirmed by PCR and LAMP (Loop-mediated isothermal amplification) on fetal tissue, uncoagulated blood samples and nasal swabs.

Canada



Four outbreaks of EHV-1 neurological disease, each involving single cases, were reported on premises in: Alberta, Quebec and Wellington. Clinical signs included: acute neurological signs, ataxia, faecal retention, urinary incontinence and vestibular disease.

France



One case of EHV-1 neurological disease was reported on a premises in Val-de-Marne. Clinical signs included ataxia. Positive diagnosis was confirmed by PCR on a nasopharyngeal swab.

Sweden



One outbreak of EHV-1 neurological disease was reported in two animals on a premises in Ostergotland. Clinical signs included: ataxia, dysuria and pyrexia. Positive diagnoses were confirmed by PCR on nasal swabs and by blood sampling. It was noted that there were a further 14 in-contacts

on site, six of which started displaying clinical signs and three of these were euthanased.

UK



One case of EHV-1 neurological disease was reported in an unvaccinated animal on a premises in North Yorkshire. Clinical signs included: colic, ataxia and urinary retention and dribbling. Positive diagnosis was confirmed by PCR on a nasopharyngeal swab.

USA



Twelve outbreaks of EHV-1 neurological disease were reported. Ten involved single cases on premises in; California, Maine, Oklahoma, Oregon, Texas, Washington and Wisconsin. One outbreak consisted of four cases stabled at the Virginia Horse Center during the Shenandoah Classic and one outbreak involved five cases on a premises in California. Clinical signs included: ataxia, bladder atony, facial nerve paresis, faecal incontinence, lack of anal/tail tone, lethargy, oedema, pyrexia, neurological signs, recumbency, tachycardia and urine dribbling.

Equine Herpes Virus-4 (EHV-4) Neurological Disease

France



One case of EHV-4 neurological disease was reported on a premises in Loiret. Clinical signs included: ataxia, exhaustion and paresis.

West Nile Virus (WNV)

South Africa



#During 2Q 2023, SAEHP reported one case of WNV on a premises in Kwa-Zulu Natal after the quarter end.

United States of America



One case of WNV was reported on a premises in Wisconsin. Clinical signs included: ataxia and shivering.

Miscellaneous Diseases

Country	AHS	Ana-plasmosis	Atypical Myopathy	Clostridial myositis	EIA	Piro-plasmosis	Potomac Horse Fever	VS
Canada	-	-	-	-	1		-	-
France	-	-	-	-	1		-	-
Ireland	-	-	1	-	-	-	-	-
South Africa	#164	-	-	-	-	#1	-	-
Switzerland	-	2	-	1	-		-	-
USA	-	-	-	-	6		1	39

#some cases reported by ICC after the quarter end

African Horse Sickness (AHS)

South Africa



#AHS is regarded as endemic in South Africa except in the AHS controlled area in the Western Cape Province. Cases have been reported from eight provinces in the country, with zero cases in the Western Cape Province. Cases were reported as follows after the quarter end: Eastern Cape (seven cases), Free State (four cases), Gauteng (76 cases), Kwa-Zulu Natal (32 cases), Mpumalanga (10 cases), Northern Cape (four cases), (North West Province (10 cases) and Limpopo (21 cases)

Anaplasmosis

Switzerland



Two outbreaks of anaplasmosis, with single cases in each, were reported on premises in the cantons of Vaud and Zurich. Clinical signs included anaemia, petechiae and pyrexia. Positive diagnoses were confirmed by PCR.

Atypical Myopathy

Ireland



#One case of atypical myopathy was reported after the quarter end.

Clostridial myositis

Switzerland



One case of clostridial myositis was reported on a premises in the Canton of Vaud. Clinical signs included pyrexia and gas gangrene myositis. Positive diagnosis was confirmed by bacteriology.

Equine Infectious Anaemia (EIA)

Canada



One case of EIA was reported on a premises in British Columbia. The affected animal had a history of co-mingling with free-roaming horses in an area where the disease is endemic.

France



One case of EIA was reported on a premises in Dordogne. Positive diagnosis was confirmed by Coggins (AGID) test.

USA



Six outbreaks of EIA were reported. Five outbreaks involved single cases on premises in; Arizona, California, Colorado, Oklahoma and Texas. One outbreak consisted of two animals on a premises in Minnesota.

Piroplasmosis

South Africa



#Piroplasmosis is regarded as endemic in South Africa and cases were reported from eight of the nine provinces in South Africa after the quarter end as follows: nine cases of *B. caballi* were reported in Gauteng. Cases of *T. equi* were reported as follows: Eastern Cape (one case), Free State (12 cases), Gauteng (30 cases), Kwa-Zulu Natal (seven cases), Mpumalanga (six cases), Northern Cape (seven cases), Western Cape (13 cases) and Limpopo (five cases).

Potomac Horse Fever

USA



One case of Potomac Horse Fever was reported on a premises in Kentucky. Clinical signs included: pyrexia, diarrhoea and generalized discomfort.

Vesicular Stomatitis

USA



Thirty-nine outbreaks of vesicular stomatitis were reported in two states, California (38 outbreaks) and Texas (one outbreak). All confirmed cases have been vesicular stomatitis New Jersey virus (VSNJV) serotype.